

ROLE OF HIGH-RESOLUTION COMPUTED TOMOGRAPHY (HRCT) TEMPORAL BONE IN DIFFERENT PATHOLOGIES

DR.HIREN DOSHI, ASSISTANT PROFESOR of ENT surgery;
DEPARTMENT OF ENT, L. G. HOSPITAL, AMC-METMEDICAL COLLEGE.
Maninagar Ahmedabad pin 380008

DR.KARNADEV SOLNAKI (3RD YEAR RESIDENT;
DEPARTMENT OF ENT, L. G. HOSPITAL, AMC-METMEDICAL COLLEGE.
Maninagar Ahmedabad pin 380008

DR. MEETA BATHLA (ASSOCIATE PROFESSOR ENT surgery);
DEPARTMENT OF ENT, L. G. HOSPITAL, AMC-METMEDICAL COLLEGE.
Maninagar Ahmedabad pin 380008

DR ATUL KANSARA (PROFESSOR AND HOD ENT surgery);
DEPARTMENT OF ENT, L. G. HOSPITAL, AMC-METMEDICAL COLLEGE.
Maninagar Ahmedabad pin 380008

DR.NAVDEEP CHAVDA (3RD YEAR RESIDENT ENT surgery);
DEPARTMENT OF ENT, L. G. HOSPITAL, AMC-METMEDICAL COLLEGE.
Maninagar Ahmedabad pin 380008

DR. RITIKSHA GAJJAR (1ST YEAR RESIDENT ENT surgery),
DEPARTMENT OF ENT, L. G. HOSPITAL, AMC-METMEDICAL COLLEGE.
Maninagar Ahmedabad pin 380008

Corresponding author: Dr. Karnadev Solanki; kdsolanki28@gmail.com

ABSTRACT

Background: -

High Resolution Computed Tomography (HRCT), a modification of routine CT, provides a direct visual window in the temporal bone providing minute structural details [1]. Purpose of the present study was to evaluate the normal variations, pathological processes (infections and congenital anomalies) and their extent involving the temporal bone along with their complications on HRCT and to correlate these imaging findings surgically.

Aim of the Study: -

To find out about the causes, different types of pathologies, male female ratio, and management accordingly.

Materials and Methods: -

The prospective study included 100 patients who were presented to ENT department of AMC MET MEDICAL COLLEGE with clinically suspected temporal bone or ear pathologies. After detailed clinical examination, the patients were subjected to high resolution computed tomography (HRCT) examination and most of them underwent surgery. The imaging findings were correlated with the surgical findings. The surgical findings were considered as final.

Observation and Results: -

Of 100 cases examined, we had 93 cases of middle ear cleft pathology (chronic Otitis media, cholesteatoma, soft tissue densities without cholesteatoma) out of which 25 cases were cholesteatoma, 22 cases of soft tissue density in mastoid cavity and 46 cases had middle ear opaque homogenous densities, 4 traumatic cases & 2 congenital pathology.

Conclusion: -

HRCT is a revolutionary imaging modality that helps in evaluating the distribution features, localization and assessing the extent of various pathologies affecting the temporal bone. The clinical and radiological findings showed a high level sensitivity with intraoperative findings as regards to the presence of cholesteatoma, changes of the ossicular chain and erosion of the lateral semicircular canal. Where criteria for cholesteatoma was soft tissue density in middle ear or mastoid with bony erosion, other cases in this study were 2 congenital cases in which the findings of HRCT were in co-relationship with the intraoperative finding. One case of facial nerve schwannoma was diagnosed on HRCT and confirmed intraoperatively. 4 cases of trauma that stated fracture of longitudinal segment of temporal bone with facial palsy. One needed surgical exploration for facial nerve decompression rest all improved by conservative management. Hence HRCT was very sensitive and specific with various pathologies confirmed intraoperatively.

KEYWORDS

Cholesteatoma, Chronic suppurative otitis media, high resolution computed tomographic scan, temporal bone pathology.

INTRODUCTION

The tympanic cavity is an air-containing space within the temporal bone, which communicates with the nasopharynx through the Eustachian tube and with the mastoid air cells by means of the tympanic antrum. It constitutes an extension of the upper respiratory tract and is subject to viral and bacterial invasion through Eustachian tube. Ear complains are the third most common reason of visiting an otorhinolaryngologist, with inflammatory conditions of the middle ear

being a frequent reason to prescribe antibiotics and perform surgery in children and teenagers [2]

Earlier, in majority of the cases, a diagnosis was made by clinical examination alone. However, with an increase in the prevalence of infective pathologies of the ear, it was suggested that the current approach to preventing and treating these conditions was not adequate. Therefore, especially in complicated and recurrent conditions, imaging plays an important role, as imaging findings may fundamentally influence the treatment [3, 4].

With the advent of helical scanning techniques, CT is increasingly the imaging study of choice for definitive preoperative temporal bone imaging [5]. HRCT is widely used in diagnosis of inflammatory middle ear diseases, various pathologies related to temporal bone and planning for surgery [6, 7].

METHOD

A prospective cross sectional study was carried out comprising of 100 patients with clinically suspected temporal bone or ear pathologies who were evaluated thoroughly by history taking, clinical examination and routine investigations. Local examination of ear was done by otoscope and microscope followed by HRCT temporal bone in all the patients.

Coronal and sagittal reformatting was done to a slice thickness of 0.5 mm. Each HRCT image were analyzed for specific features relevant to the evaluation of pathologies of temporal bone and interpreted in detail to define:

1. The type, location and extent of lesion.
2. Bony erosions of middle ear walls.
3. The integrity of the ossicular chain, facial nerve canal and labyrinth.
4. Involvement of hidden area, mastoid air cell system.

Inclusion criteria:-

- Patients who are clinically suspected of having symptoms related to temporal bone.
- History of ear discharge, trauma to head, history of facial palsy, hearing loss.
- Suspecting middle ear, mastoid or temporal bone pathology.

Exclusion criteria:-

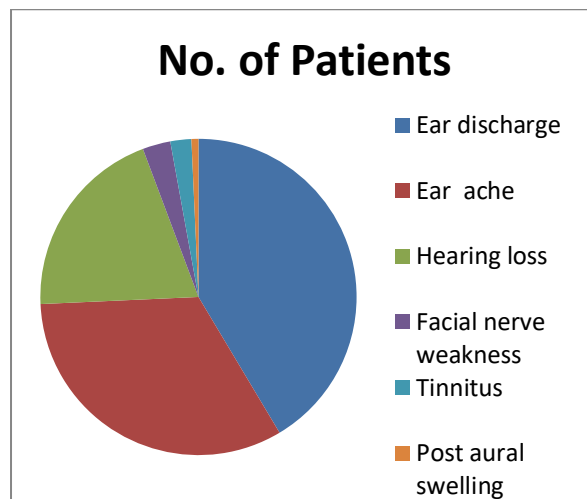
- Patients with electric devices at the skull base, such as cochlear implants.
- Patients not willing for participation in the study
- Patients not willing for HRCT or surgery

OBSERVATION AND RESULT

Out of 100 patients included in the study, surgical exploration was done in 97 cases. In this study, the youngest patient was of 1.5 years and the eldest was of 65 years.

The distribution of diseases diagnosed by HRCT, had maximum cases were infections (93) followed by traumatic (4), congenital (2), tumors (1). Sex distribution of the study stated that 64 Males and 36 Females were affected. On comparing the presenting complains of the patients, ear discharge was most common (58) followed by Ear ache (46), Hearing loss (28) and facial weakness (4), tinnitus (8), post aural swelling (1).

Table 1: Clinical Features		
Clinical features	No. of Patients	Percentage %
Ear discharge	58	58
Ear ache	46	46
Hearing loss	28	28
Facial nerve weakness	4	4
Tinnitus	3	3
Post aural swelling	1	1

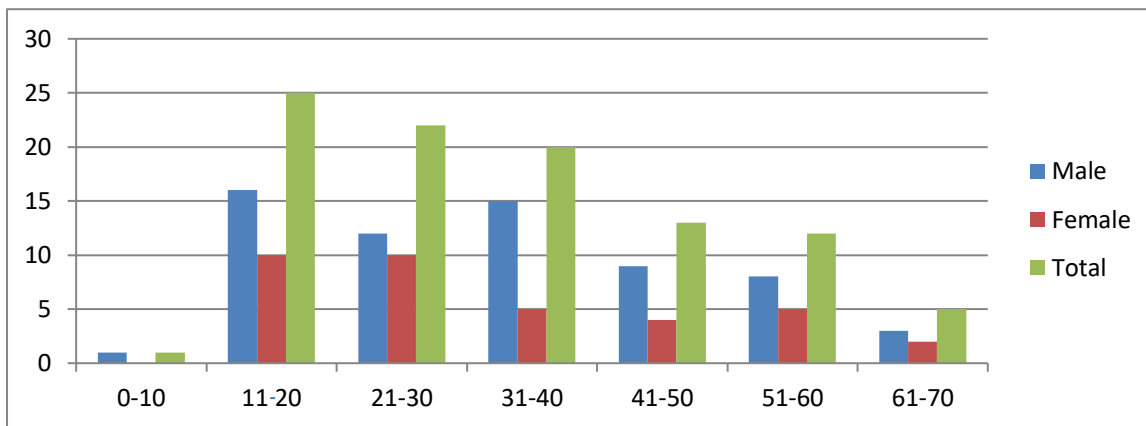


Graph 1. Clinical Features

Table 2 shows the age & sex distribution of the patients having pathologies of temporal bone. Here 11-20 years age group had maximum pathologies while least pathology was seen in 0-10 years age group which were congenital.

Table 2: Age and sex distribution of pathology.

Age	Male	Female	Total	%
0 – 10	01	00	01	1
11-20	16	10	26	26
21-30	12	10	22	22
31-40	15	05	20	20
41-50	09	04	13	13
51-60	08	05	13	13
61-70	03	02	05	5
Total	52	42	100	100

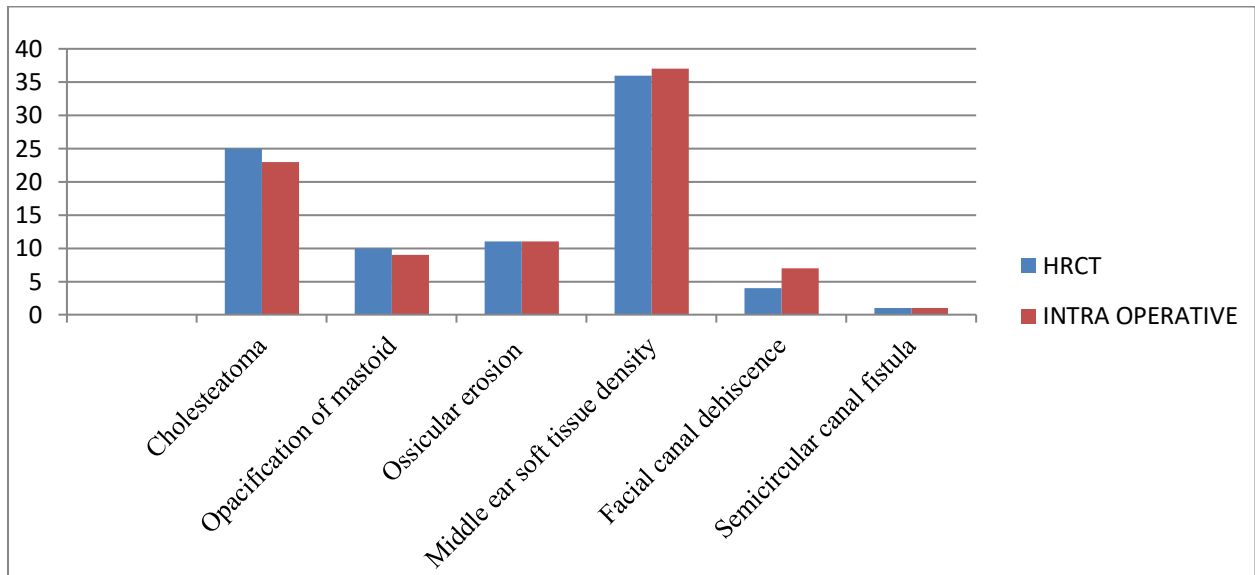


Graph 2. Age and sex distribution of pathology.

On distribution of infections from HRCT, middle ear homogenous collection was most common followed by cholesteatoma and Soft tissue density in mastoid cavity. HRCT diagnosis of cholesteatoma was made in 25 patients. Out of these 25 patients, intraoperative findings of CSOM with cholesteatoma were seen in 23 (92%) and CSOM without cholesteatoma in 02 (8%). There were 23 patients that HRCT diagnosed accurately. Two patients were over diagnosed by HRCT. CT scans of chronically draining ears demonstrated abnormal soft tissue densities in the middle ear or mastoid. However, if this soft tissue mass was not associated with bone erosion, it was not possible to confer whether or not cholesteatoma was present. In this study, my criteria for cholesteatoma in HRCT were soft tissue density with bony erosion. HRCT diagnosed facial canal dehiscence in 4 patients while intraoperative it was in 7 patients. Ossicular erosion was found in 11 patients on HRCT. During surgery, ossicular erosion was found in 11 patients. Opacification of mastoid on HRCT seen in 10 cases. During surgery, it was found in 09 cases. Correlation between HRCT and intraoperative findings in cholesteatoma, facial canal dehiscence, opacification of mastoid, lateral semicircular canal fistula, soft tissue density and ossicular erosion is shown in [Table-3] showing the sensitivity/ specificity in these respective entities.

Table 3: Comparison between CT and operative finding in ear infections.

	HRCT	INTRA OPERATIVE	TRUE +VE	TRUE -VE	FALSE +VE	FALSE -VE	SENSITIVITY	SPECIFICITY
Cholesteatoma	25	26	23	72	02	03	88%	97%
Opacification of mastoid	10	09	09	90	01	00	100%	99%
Ossicular erosion	11	11	11	89	00	00	100%	100%
Middle ear soft tissue density	36	37	36	60	03	01	97%	95%
Facial canal dehiscence	04	07	04	93	00	03	57%	100%
Semicircular canal fistula	01	01	01	99	00	00	100%	100%



Graph 3. Comparison between CT and operative finding in ear infections

Table 4 shows HRCT and intraoperative comparison of the pathology of temporal bone other than infection which included facial nerve schwannoma, a case of traumatic facial palsy, and two congenital cases including Mondini's Dysplasia and external canal atresia. Only those patient undergoing surgery were included in this comparison out of all traumatic cases

TABLE 4 Comparison between CT and operative finding in other pathologies		
	HRCT	INTRA-OPERATIVE
FACIAL NERVE SCHWANNOMA a.OSSICLES b.FAICAL NERVE c.FACIAL NERVE CANAL d.SEMICIRCULAR CANAL e.MIDDLE EAR AND MASTOID f.INNER EAR g.COCHLEAR NERVE f.OTHER	NORMAL NORMAL NORMAL NORMAL NORMAL NORMAL Hypodense lesion noted with widening of stylomastoid foramen	NORMAL NORMAL NORMAL NORMAL NORMAL NORMAL Lesion was identified and removed
MONDINI'S DYSPLASIA a.OSSICLES b.FAICAL NERVE c.FACIAL NERVE CANAL d.SEMICIRCULAR CANAL e.MIDDLE EAR AND MASTOID f.INNER EAR g.COCHLEAR NERVE	NORMAL NORMAL NORMAL NORMAL NORMAL Enlarged Vestibular aqueduct NORMAL	NORMAL NORMAL NORMAL NORMAL NORMAL Gusher seen NORMAL
Trauma a.OSSICLES b.FAICAL NERVE c.FACIAL NERVE CANAL d.SEMICIRCULAR CANAL e.MIDDLE EAR AND MASTOID f.INNER EAR g.COCHLEAR NERVE f.OTHER	NORMAL NORMAL NORMAL NORMAL haemotympanum NORMAL NORMAL transverse fracture noted in temporal bone	NORMAL NORMAL NORMAL NORMAL Collection noted NORMAL NORMAL Fracture segment seen and decompression done
External ear atresia a.OSSICLES b.FAICAL NERVE c.FACIAL NERVE CANAL d.SEMICIRCULAR CANAL e.MIDDLE EAR AND MASTOID	Eroded NORMAL NORMAL NORMAL Thickening of mucosa	Eroded NORMAL NORMAL NORMAL Granulations and soft tissue densities

f.INNER EAR	NORMAL	NORMAL
g.COCHLEAR NERVE	NORMAL	NORMAL

DISCUSSION

HRCT imaging is necessary for anatomic determination of chronic Otitis media, suspicion of congenital anomalies and to detect any loss of surgical landmarks prior to operation [8]. Watts et al. have shown that HRCT is less expensive and provides useful information about surgical trend [9] and, thus, if a co-ordination can be made between the otologist and radiologist with an appropriate familiarity of the surgeon with HRCT scans, preoperative imaging is essential and very helpful. Knowledge of the mastoid pneumatization aids in the planning of surgical approach e.g. whether to do canal wall down or up type of surgery [10].

Hence the present study was carried out with an aim to study any normal variation, congenital anomalies in the structure of temporal bone and to evaluate various infective pathologies of temporal bone and their complications with HRCT.

In our study male were more commonly affected and male to female ration was 1.77:1. Similar results were seen in studies of Poursadegh et al., which reported a male to female ratio of 1.39:1 [11] and Gerami et al., had a highly skewed male to female ratio of 2.48:1 [12].

The most frequently encountered pathological process associated with unsafe type of CSOM is cholesteatoma. Acquired cholesteatomas are commonly seen in patients less than 30 years .In our study too, we found that the majority of patients were aged less than 30 years. which are similar to findings by Gerami et al.,[12] & Datta et al., [13] .

According to [14] Mafee et al., the hallmark of cholesteatoma on HRCT is a soft tissue mass in attic and mastoid antrum associated with smooth bony expansion, scalloping of mastoid, erosion of lateral wall of attic (Scutum) and erosion of ossicles.

Cholesteatoma characteristically causes bone erosion and when this feature was present in association with a soft tissue mass on CT, both Jackler et al., and O'Donoghue et al., found cholesteatoma to be present in 80% of cases explored [7,15]. Using the same criteria, we detected 23 out of 25 cases of cholesteatoma on surgical exploration. From 36 cases showing middle ear soft tissue density 3 cases were diagnosed cholesteatoma during surgery while 37 cases showed middle ear soft tissue density which states 4 cases were wrongly diagnosed on HRCT.

In our study, HRCT diagnosed facial canal dehiscence in 4 cases .Facial canal dehiscence was found to be present in 7 patients intraoperatively. There were only 4 patients that were accurately diagnosed by HRCT, in other similar study similar results were found by Alzoubi et al., Garber et al., and Garg et al., [16-18]. In HRCT 11 cases showed ossicular erosion which was similar in finding during operation thus was 100% sensitive and specific. Semi circular canal dehiscence was seen in 1 patient on HRCT and surgery also. Out of 2 congenital cases one was external ear canal atresia which had conductive hearing loss and was operated for it. Other case was of Mondini's dysplasia and underwent Cochlear implant. One case of tumor was diagnosed by HRCT (Facial nerve schwannoma) and was operated successfully for it.

1 congenital case was of congenital external canal atresia which underwent HRCT and was diagnosed that middle and inner ear was normal accordingly surgical intervention was done and was found that only pathology was of external ear with conductive hearing loss. Other case of congenital deformity was Mondini's dysplasia which stated that external and middle ear was normal but it had enlarged vestibular aqueduct thus during surgery it was encountered as gusher on during cochleostomy. Out of 4 cases of trauma all stated transverse fracture of tympanic segment of temporal bone from then 3 improved conservatively. 1 cases had to undergo facial nerve decompression surgery which stated that middle ear had fluid in it with rest all normal.

The results of present study thus indicated that HRCT is a useful modality through which pre-operative assessment of temporal bone pathologies can be done efficiently with a reasonable accuracy and precision for taking surgical decisions. Although, the present study has a limitation of sample size and showed that despite disagreement over some entities like facial canal dehiscence, the broad diagnosis of HRCT had a good agreement with surgical findings, thus indicating that prudent use of HRCT with a good clinical judgment provided a basis for preparation of a diagnosis that guide the surgical decisions in the right directions.

Conclusion

In my study HRCT played an important role in diagnosing the pathologies. From 100 patients undergoing HRCT 26 cases had cholesteatoma, 37 cases had chronic Otitis media with granulations or middle ear soft tissue densities, other cases of middle ear soft tissue and mastoid cavity soft tissue had underlying ossicular deformity or facial nerve canal dehiscence or semicircular canal dehiscence; Thus by HRCT it helps in approach for the surgery for a limited cholesteatoma, we can go for inside out technique and for extensive case post aural approach with radical mastoidectomy can be planned. The clinical and radiological findings showed a high level sensitivity with intraoperative findings as regards to the presence of cholesteatoma, changes of the ossicular chain and erosion of the lateral semicircular canal. Where criteria for cholesteatoma was soft tissue density in middle ear or mastoid with bony erosion, other cases in this study were 2 congenital cases in which the findings of HRCT were in co-relationship with the intraoperative finding. One case of facial nerve schwannoma was diagnosed on HRCT and confirmed intraoperative. 4 cases of trauma that stated fracture of longitudinal segment of temporal bone with facial palsy. One needed surgical exploration for facial nerve decompression rest all improved by conservative management. Hence HRCT was very sensitive and specific with various pathologies confirmed intraoperative.

HRCT scan of temporal bone depicts complex bony details and associated soft tissue pathologies accurately. The results of the present study showed a good agreement between HRCT and operative findings. HRCT temporal bone is an efficacious modality for accurate delineation of the anatomy and pathological involvement of temporal bone. We can hence conclude HRCT is useful for diagnosis, surgical planning and management of temporal bone pathologies.

REFERENCES

- (1) CL Thukral et al., Role of High Resolution Computed Tomography in Evaluation of Pathologies of Temporal Bone; *Journal of Clinical and Diagnostic Research*. 2015 Sep, Vol-9(9): TC07-TC10..
- (2) Brogan M, Chakeres DW. Computed tomography and magnetic resonance imaging of the normal anatomy of the temporal bone. *Semin Ultrasound CT MR*.1989;1010:178- 94.
- (3) Chakeres DW, Augustyn MA. Temporal bone. In: Haaga JR., Lanzieri CF, Gilkeson RC. CT and MR Imaging of the Whole Body. 4th ed. Ohio, Mosby, 2003: 495-512.
- (4) Alexander AE, Caldemeyer KS, Rigby P. Clinical and surgical application of reformatted high resolution CT of the temporal bone. *Neuroimaging Clin N Am*. 1998;8(3):631-50.
- (5) Alexander AE, Caldemeyer KS, Rigby P. Clinical and surgical application of reformatted [4] high resolution CT of the temporal bone. *Neuroimaging Clin N Am*. 1998;8(3):631-50.
- (6) Tono T, Miyanaga S, Morimitsu T, Matsumoto I. Computed tomographic evaluation [5] of middle ear aeration following intact canal wall tympanoplasty. *Auris Nasus Larynx*. 1987;14(3):123-30.
- (7) Jackler RK, Dillon WP, Schindler RA. Computed tomography in suppurative ear disease: [6] a correlation of surgical and radiographic findings. *Laryngoscope*. 1984;94(6):746-52.
- (8) Yates PD, Flood LM, Banerjee A, Clifford K. CT scanning of middle ear cholesteatoma: what does the surgeon want to know? *Br J Radiol*. 2002;75:847- 52.
- (9) Watts S, Flood LM, Banerjee A, Clifford K. A systematic approach to interpretation of computed tomography scans prior to surgery of middle ear cholesteatoma. *J Laryngol Otol*. 2000;114:248-53.
- (10) hee NW, Tan TY. The Value of Pre-operative High resolution CT Scans in Cholesteatoma surgery. *Singapore Med J*. 2001;42(4):155-59.
- (11) Poursadegh M, Hashemi G, Jalali M. Evaluation of Anatomical Variations of vestibular aqueduct dimensions in temporal bone CT scan. *MJIRI*. 2000;14(3):199-202.
- (12) Gerami H, Naghavi E, Wahabi-Moghadam M, Forghanparast K, Akbar MH. Comparison of preoperative computerized tomography scans imaging of temporal bone with the intra-operative findings in patients undergoing mastoidectomy. *Saudi Med J*. 2009;30(1):104-08.
- (13) Datta G, Mohan C, Mahajan M, Mendiratta V. Correlation of preoperative HRCT findings [12] with surgical findings in Unsafe CSOM. *IOSR Journal of Dental and Medical Sciences (IOSR-JDMS)*. 2014;13(1):120-25.
- (14) Mafee MF, Levin BC, Applebaum EL, Campos M, James CF. Cholesteatoma of the middle ear and mastoid. A comparison of CT scan and operative findings. *OCNA*. 1988;21(2):265–293.
- (15) O’Donoghue GM, Bates GJ, Anslow P, Rothera MP. The predictive value of high resolution computerized tomography in chronic suppurative ear disease. *Clin Otolaryngol Allied Sci*. 1987;12(2):89-96.
- (16) Alzoubi FQ, Odat HA, Al-Balas HA, Saeed SR. The role of pre-operative CT scan in [24] patients with chronic otitis media. *Eur Arch Otorhinolaryngol*. 2009;266:807-09.
- (17) Garber LZ, Dort JC. Cholesteatoma: diagnosis and staging by CT scan. [25] *J Otolaryngol*. 1994;23(2):121-24.

- (18) Garg P, Kulshreshtha P, Motwani G, Mittal MK, Rai AK. Computed tomography in [26] chronic suppurative otitis media: value in surgical planning. *Indian J Otolaryngol Head Neck Surg.* 2012;64(3):225-29.