

**MANAGEMENT OF METACARPAL SHAFT FRACTURE WITH CERCLAGE WIRING AND ITS
OUTCOME**

**Dr. Sankit Shah, Dr. Nilesh Ghelani, Dr. Arvind Kaushal, Dr. Hardik Ponkiya, Dr. Darshil Rajgor,
Dr. Shukan Kapadia**

Contributors

**1. Dr. Sankit D. Shah M.Ch. (Assistant professor) email id- drsankitshah@gmail.com,
9727770900 (First author)**

**2. Dr. Nilesh B. Ghelani M.Ch. (Associate professor), email id- drnileshghelani@yahoo.co.in,
9825530037(corresponding author)**

**3. Dr. Arvind Kaushal (M.Ch. 3rd year resident), email id- dr.arvindkaushal@gmail.com,
9873876561**

**4. Dr. Shukan Kapadia (M.Ch. 2nd year resident), email id- shukankapadia@gmail.com,
9979978953**

**5. Dr. Ashish Hadiyal (M.Ch. 1st year resident), email id- ashish_hadiyal3@yahoo.com,
8010482425**

Department and institution: Department of Burns and plastic surgery, Smt. SCL hospital, Smt.

NHL Medical College, Saraspur, Ahmedabad, Gujarat -380018

Subject – Plastic Surgery

Conflicts of interest - NIL

Abstract

Introduction: Hand is specialized organ of the body performing complex functions, and it enables a person to earn his livelihood. Various options are there for treatment of metacarpal shaft fractures, in this study we treated patients with cerclage wiring and noted its outcomes.

Material and methods: patients who were presented with oblique/spiral fracture of shaft of metacarpal during the study period were treated with cerclage wiring and followed until they were able to return to work.

Results: seven patients with eight fractures were treated during the study period. Reduction achieved was good in all patients. We had one late complication of wire breakage and no malunion or non-union occurred.

Conclusion: we conclude that cerclage wiring treatment is effective method for treatment of oblique/spiral fracture of metacarpals and a viable and cheap alternative to plate and screw method in low socio-economic patients.

Keywords: metacarpal shaft fracture, spiral/oblique fracture, cerclage, ss wire

Introduction

Hand is specialized organ of the body performing complex functions, ranging from daily routine activities at home to various other coarse and fine motor functions at workplace and it enables a person to earn his livelihood. Trauma to hand occurs commonly especially fractures of small bones and improper treatment results in increased morbidity and decreased functional ability as demonstrated by Watson-jones¹.

Various factors are to be considered while deciding the appropriate treatment for the metacarpal fractures and minimize the associated morbidities. In this study we focused on cerclage wiring treatment, its results and outcomes. Hands have five metacarpal bones which articulate with carpal bones proximally and with respective phalanges distally.

Metacarpal shaft fracture can be transverse, oblique/spiral, and comminuted. Treatment of metacarpal shaft fractures ranging from cast immobilization for undisplaced/minimally displaced fracture to open reduction and internal fixation for unstable displaced fractures.

Improper treatment leads to various complications of which rotational deformity and shortening are more morbid, interfering with hand functions. There also occur depression of knuckle and volar prominence of the head of the metacarpal which not only interfere with functioning of the hand but also cosmetically not acceptable to the patient.

Material and methods

This study was done in our department from Jan 2018 to Jan 2019. All patients with oblique/spiral fracture of metacarpal shaft who were treated with cerclage wiring included in the present study.

Operative technique

All patients were treated under wrist block and tourniquet was not used. A vertical skin incision is given directly over affected metacarpal, and deepens. Extensor tendons identified and carefully retracted to one side of the wound. Interossei muscle carefully dissected off the metacarpal and fracture site identified. Fracture reduced and held in position. A plane is developed circumferentially avoiding injury to vital structures. With the help of right angle forceps 26 gauge pre stretched ss-wire looped around the fractures at two places. SS-wire is then twisted with fracture held in reduced position. We do not score the shaft of the metacarpal bone. Reduction is checked under C-arm and if satisfactory wound is closed in single layer. Cock-up splint is given for 10 days following which, patient is assessed for range of motion and physiotherapy is advised. Patients were followed upto they were ready to go to work and were assessed for any complication and active range of motion achieved.

Results

During the study period, 7 patients were presented with 8 oblique/spiral fracture of shaft of metacarpal bone and treated with cerclage wiring were included in present study. The subject data and outcomes are summarized in Table 1. Out of 7 patients 4 were female and 3 were male. Right hand bones were involved in 4 and left hand bones in 3 patients. Age of the patients ranges from 17-40years with an average age of 29 years. 5th finger involved in three,

4th in two, 3rd in two, 2nd in one and one patient presented with fracture of two bones while rest have single bone fractured. No. of wire used is 2 per fracture. Post-op recovery was uneventful in all patients. No patient had malunion or non-union. We had one late complication related to ss-wire, one patient present after 1 year of treatment with swelling over scar, which on evaluation with x-ray shows breakage of one ss-wire and with no involvement of bone resulting in abscess formation which was subsequently removed under local anaesthesia and C-arm and patient recovered. All patients obtained a full range of motion of the injured and uninjured fingers at a mean final follow-up of 6 (range 5–7) weeks. This full range of motion was reached in all patients between 2 and 3 weeks after surgery. The average time to return to work was 4 (range 3–7) weeks.

Table 1

Sr. no.	Age/sex	Bone involved	complication	Range of motion	Follow up (weeks)

1	32y/m	Rt 3 rd metacarpal	Nil	Full	6
2	29y/m	Left 2 nd & 3 rd metacarpal	wire breakage	Full	6
3	32y/f	Left 5 th metacarpal	Nil	Full	5
4	40y/f	Rt 5 th metacarpal	Nil	Full	7
5	17y/f	Rt 4 th metacarpal	Nil	Full	6
6	32y/f	Lt 5 th metacarpal	Nil	Full	7
7	21y/m	Rt 4 th metacarpal	Nil	Full	6

Case 1: a 32y old male presented with oblique/spiral fracture of right 3rd metacarpal and treated with cerclage wiring, note the reduction achieved. (Fig -1)

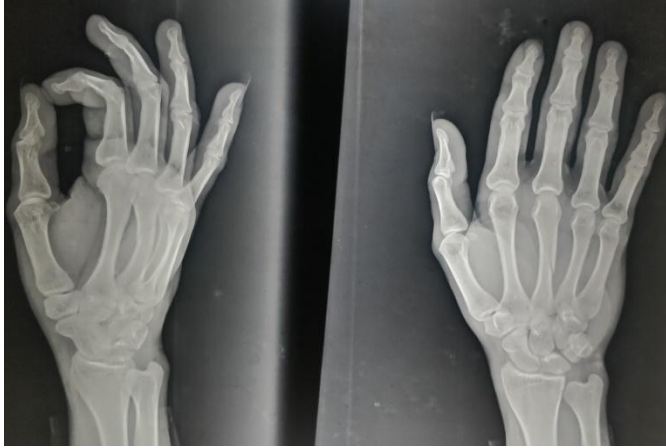

Fig 1a- oblique/spiral fracture of right 3rd metacarpal

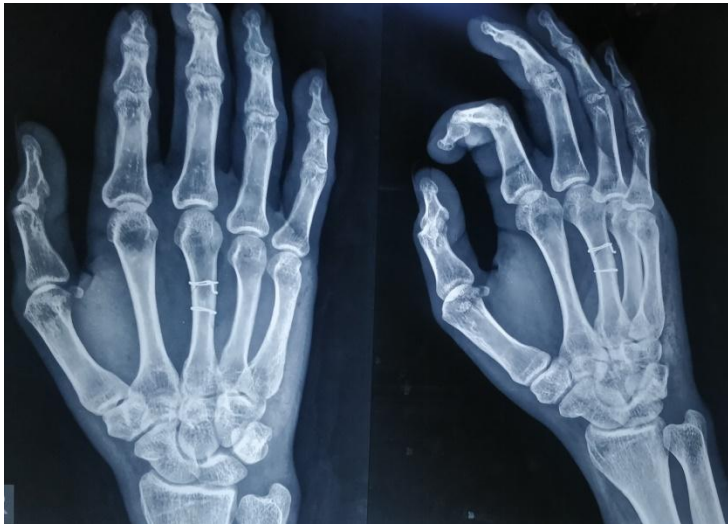

Fig 1b- post op x-ray, note the reduction achieved.

Case 2

A 21yr old male presented with right 4th metacarpal oblique/spiral fracture and treated with cerclage wiring.

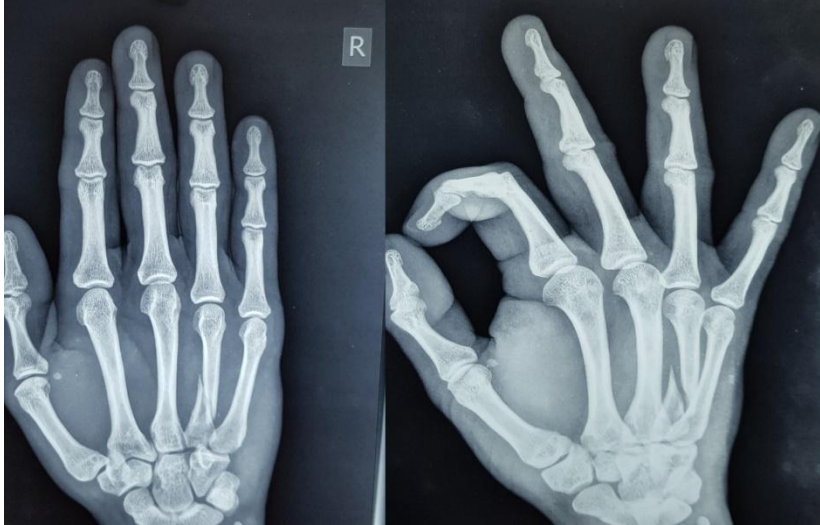


Fig 2a) oblique/spiral fracture of right 4th metacarpal note the displacement and angulation

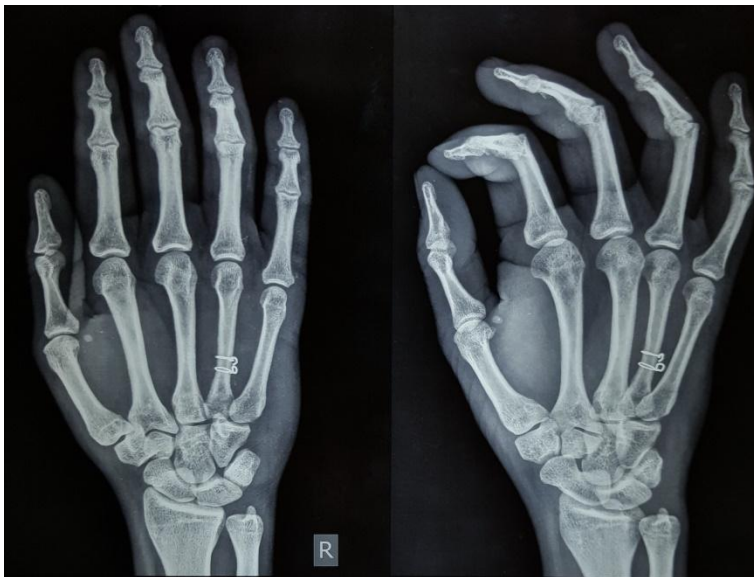


Fig 2b) post-op x-ray, note the reduction achieved.

Discussion

Treatment of hand fractures is evolved from simple immobilization of the hand to plate and screw fixation. At our center we treat hand fracture with immobilisation, k-wire fixation, osteo-distractor fixation and plate and screw fixation. During the study period we treated oblique/spiral fractures with cerclage wiring technique.

Cerclage wiring for the treatment of the metacarpal fractures was first described by Gropper et al², in their study they treated 21 metacarpal fractures with cerclage wiring technique. They scored the bone in all cases with a side-cutting burr to prevent wire migration. The fingers were immobilised for 10 to 14 days after surgery. Seventeen patients had a full range of motion at final follow-up and the remaining four patients had minor losses of range of motion. The average time to return to work after surgery was 7 weeks.

As described by AL-QATTAN et al³, we also do not score the metacarpal shaft prior to wiring but we immobilised the hand in cock-up splint for two weeks. They treated 26 patients with cerclage wiring technique and also discussed the factors why this technique is not so popular. Also they conclude that cerclage wiring fixation provides enough stability to allow early mobilisation of finger but they advocate wrist immobilization in every case.

Rhineland^{4, 5} studied the effects of cerclage-wiring on long bones first in dogs and later in human. He found that the afferent blood supply to the cortex comes from medullary cavity in centrifugal manner. So, risk of hampering the blood supply by the circumferential cerclage wire is minimal as there is no reporting of malunion/non-union in any study as in our study too

As compared to other techniques, cerclage wiring seems to give fairly good results with minimal complications. Like k-wire provides anatomical reduction but it requires prolonged period of immobilization and rate of shortening, rotational deformity and delayed union is high. Lag

screws are considered the strongest, it can be inserted in a relatively short time, but is technically demanding, relatively expensive, requires special equipment, may require late removal and is less “forgiving”⁶.

Luhr miniplates are also employed for metacarpal shaft fracture fixation providing strong fixation for early mobilization but is expensive, require experience and requires special equipment.

In comparison cerclage wiring technique is easy method of open fixation, relatively cheap, require no special equipment and provide enough stability for early mobilization with minimal complications. One we had is late complication of wire breakage which requires removal because of abscess formation.

Conclusion

We conclude that cerclage wiring treatment is effective method for treatment of oblique/spiral fracture of metacarpal shaft and a viable and cheap alternative to plate and screw method in low socio-economic patients in country like our where cost is still the deciding factor.

References

1. Watson-jones, R.: fractures and joint injuries, vol., ed. 5. Edinburgh, Churchill-livingstone, 1976, pp.777-780.
2. Gropper PT, Bowen V. Cerclage wiring of metacarpal fractures. Clinical Orthopaedics and Related Research,1984, 188: 203–207.
3. Al-Qattan MM, Al-Lazzam A. long oblique/spiral mid-shaft metacarpal fractures of the fingers: treatment with cerclage wire fixation and immediate post-operative finger mobilisation in a wrist splint. J Hand Surgery Eur Vol, 2007, 32: 637–640.
4. Rhinelander FW. The normal microcirculation of diaphyseal cortex and its response to fracture. Journal of Bone and Joint Surgery. 1968, 50A: 784–800.
5. Rhinelander FW. Minimal internal fixation of tibial fractures.Clinical Orthopaedics and Related Research. 1975, 107:188–220.
6. Diao E. Metacarpal fixation. Hand Clinics. 1997, 13: 557–571.