

## 6 TRENDS AND OUTCOME OF EMERGENCY SURGERY FOR DUODENAL ULCER PERFORATION

Authors :

Dr Erbaz Riyaz Momin Assistant Professor, Department of Surgery. Dr RN Cooper Municipal General Hospital & HBT, Medical College. Mumbai ,Dr Jayshree S Pandya Professor, Department of Surgery, BYL Nair Ch. Hospital & TN Medical College, Mumbai. Dr Sonali Bhagwat Consultant Surgeon, Global Hospitals, Mumbai

### **Abstract:**

**Context:** Duodenal Ulcer Perforation

**Aims:** The aim of the study is to see the trends and analyse the outcome of perforated duodenal ulcer.

**Settings and Design:** Retrospective study- retrospective review of case records.

### **Methods and Material:**

Case records of 302 patients of DUP presented to a tertiary teaching institute between January 1992 and June 2004 were retrospectively analysed. Various parameters like age, gender, duration of symptoms, comorbidity, leucocyte count, peritoneal contamination, size of perforation, procedure performed and its outcome were studied.

All cases operated for DUP only were included.

**Statistical analysis used:** -

**Results: Observations & Results:**

302 patients [274 (90.73%) males and 28 (9.27%)females] underwent surgical procedure for a perforated DUP in this institute. 5 (1.66%) patients underwent a definitive procedure while the rest 297 (98.34%) underwent primary omental patch.

75 (24.83%) patients developed infective complications. 18 (5.96%) of patients developed a bile leak following the surgery. 12 (3.97%) of total patients expired whereas the rest 290 were discharged .

### **Conclusions:**

The presentation of patients, trend of surgical procedure and the associated morbidity and mortality is similar to other studies. In our study, incidence of emergency surgery and consequently leak rate and mortality has increased in early 2000s this could be attributed to changing patient demographics and needs to be studied further.

**Key-words:** Duodenal Ulcer perforation, Emergency surgery, Leak rate,

Introduction:

### **Introduction**

Peptic Duodenal ulcer is one of the common GI disorders. With the increased use of H2 receptor blocker, or proton pump inhibitor and increased availability of fiberoptic endoscopy; the

hospital admissions and elective surgeries for Duodenal Ulcers have significantly reduced over the past three decades [1,2,3,4,5].

However, the incidence of emergency surgery and mortality associated with peptic ulcers has not decreased as expected. On the contrary recent studies suggest an increase in the rates of hospitalisation and mortality in elderly patients for peptic ulcer complications of perforation and bleeding [4,5].

Duodenal Ulcer Perforation (DUP) is the second most common complication of peptic ulcer Disease and may become a more common indication for emergency surgery than bleeding. Surgery is almost always needed for DUP [3,4,5].

In a DUP the surgical options are simple patch closure, simple patch closure with highly selective vagotomy (HSV), or Patch closure with Vagotomy and Drainage. Presently the simple patch closure is one of the most commonly performed surgeries for DUP [3,4,5]

There is a huge amount of information on DUP and its management but not much studies are available in Indian scenario hence the need for a study. The aim of the study is to see the trends and analyse the outcome of perforated duodenal ulcer.

---

These patients were posted for surgery after taking detailed history and all investigations done as required for surgery. All the patients with diabetes were evaluated for blood sugar levels and taken

### **Subjects and Methods:**

### **Materials and Methods**

**302** patients of DUP presented to a tertiary teaching institute between January 1992 and June 2004. Case records of these patients were retrospectively analysed for:

- 1- Age and gender.
- 2- Duration between onset of symptoms and admission
- 3- Co-morbid conditions associated
- 4- Total leucocyte count on admission
- 5- Amount of contamination
- 6- Site and size of perforation and chronicity.
- 7- Type of procedure performed
- 8- Outcome and complications of procedure

Inclusion criteria: All cases operated for DUP only were included. Cases were not restricted by age or gender or religion.

Exclusion criteria

Patients undergoing surgery for gastric or bowel perforation, or traumatic duodenal perforations were excluded.

The patients included in the study are not from any particular unit or surgeon. They represent all the patients presenting to the institute. Also, as this institute is a teaching hospital most of these cases have been performed by residents under assistance/supervision by faculty.

History and Examination:

The admission details and case records of the patients included in the study were retrieved and studied retrospectively. From the records the details like- age, gender, the onset of symptoms, chronicity, total leucocyte count, presence of co-morbid conditions and NSAID use were noted down.

The operative records were studied and the details of amount of contamination, site, size, acute or chronic nature of perforation and the type of procedure performed were noted.

The further progress of patient in terms of complications, morbidity, mortality, and outcome were noted.

As a principle in this institute nasogastric tube and abdominal drains are placed in all patients operated for perforation.

Results:

### **Observations & Results:**

From January 1992 to June 2004 there were 302 patients [274 (90.73%) males and 28 (9.27%) females] who underwent surgical procedure for a perforated DUP in this institute [Chart 1]. 5 (1.66%) patients underwent a definitive procedure in the form of truncal vagotomy, gastrojejunostomy with feeding jejunostomy while the rest 297 (98.34%) underwent primary omental patch.

Presentation:

DUP presented in the age group of 13-90 years, the mean age being 41.10 yrs. The perforated ulcer was located in the anterior wall of the first part of duodenum. No posterior perforated ulcer was noted [Table 1].

Most of the patients presented to the hospital between 4-72 hours of onset of symptoms, mean being 11.37 hours. On presentation the patients mean pulse was 95.47 bpm (range 78-124) and the mean blood pressure was systolic 111.65 (range 80-160), diastolic 71.77 (range 30-98) mm of Hg. The mean total leucocyte count was 8271.3 (range 6000 – 21870) /ml. The mean peritoneal contamination was 718.28 (range 300- 2000) ml. The mean size of perforation was 7.08 (range 2-20) mm [Table 1].

Co-morbid condition

54 (17.88%) of all patients with DUP were associated with a pre-existing co-morbid condition. 16 (5.3%) of patients had a history of NSAID consumption. 7 (2.3%) of patients had a history of Chronic DU.

#### Outcome

75 (24.83%) patients developed infective complications. 18 (5.96%) of patients developed a bile leak following the surgery [Chart 2]. 12 (3.97%) of total patients expired whereas the rest 290 were discharged [Chart 3].

Chart 1

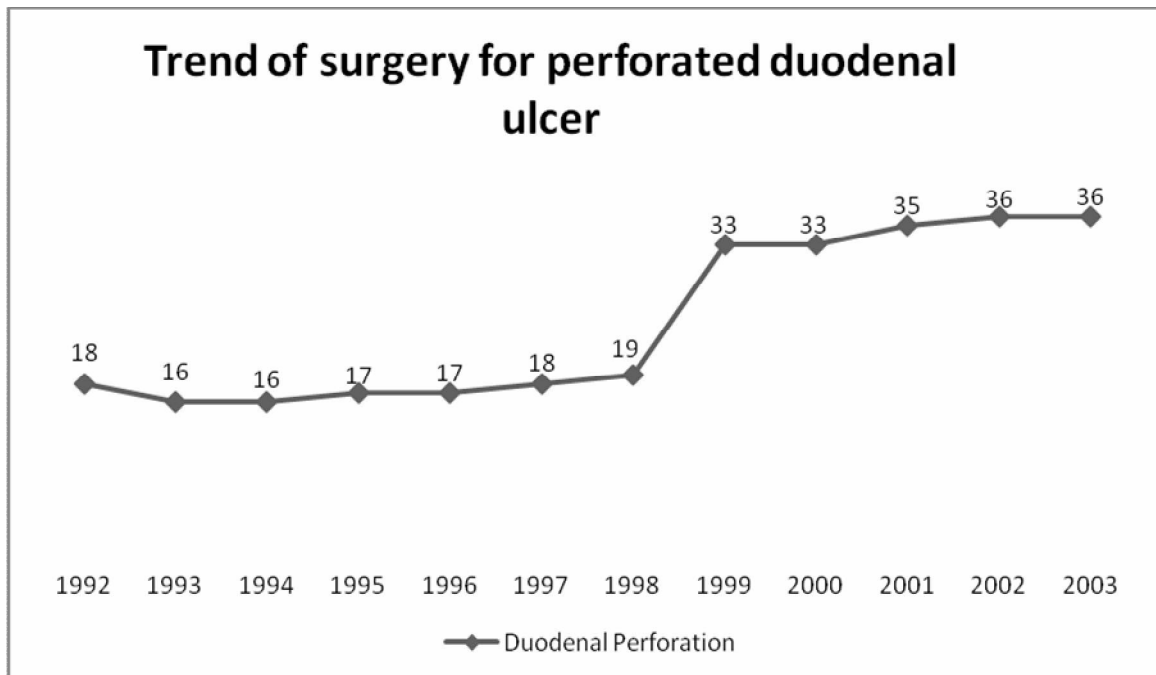


Chart 2

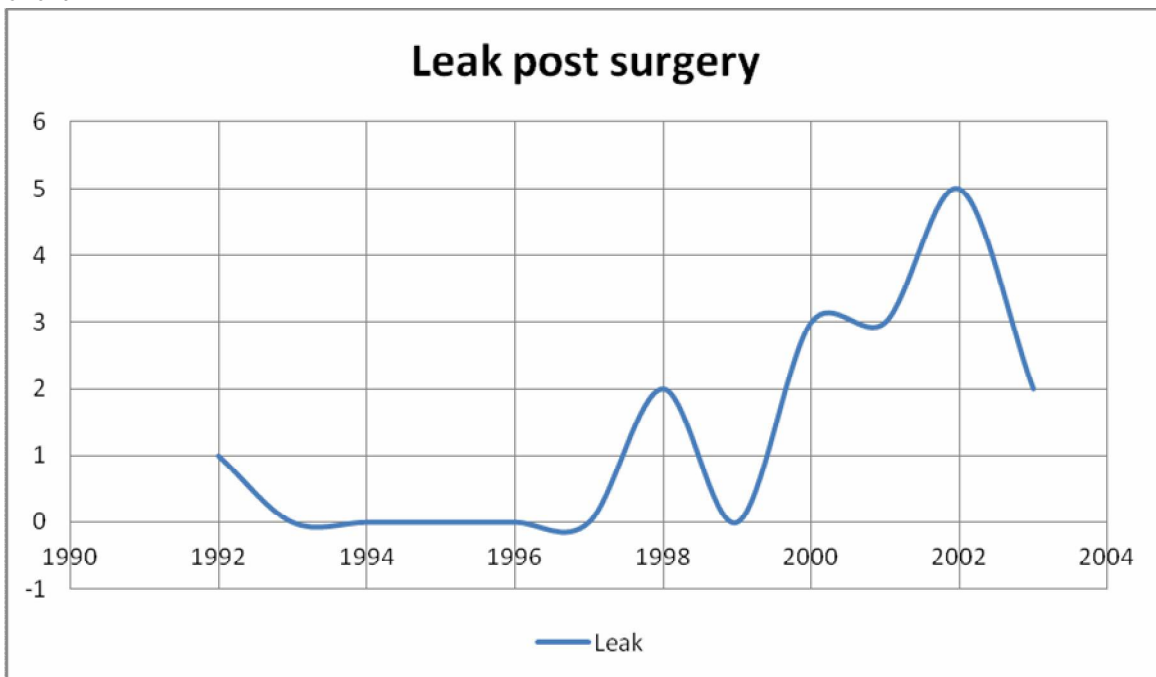


Chart 3



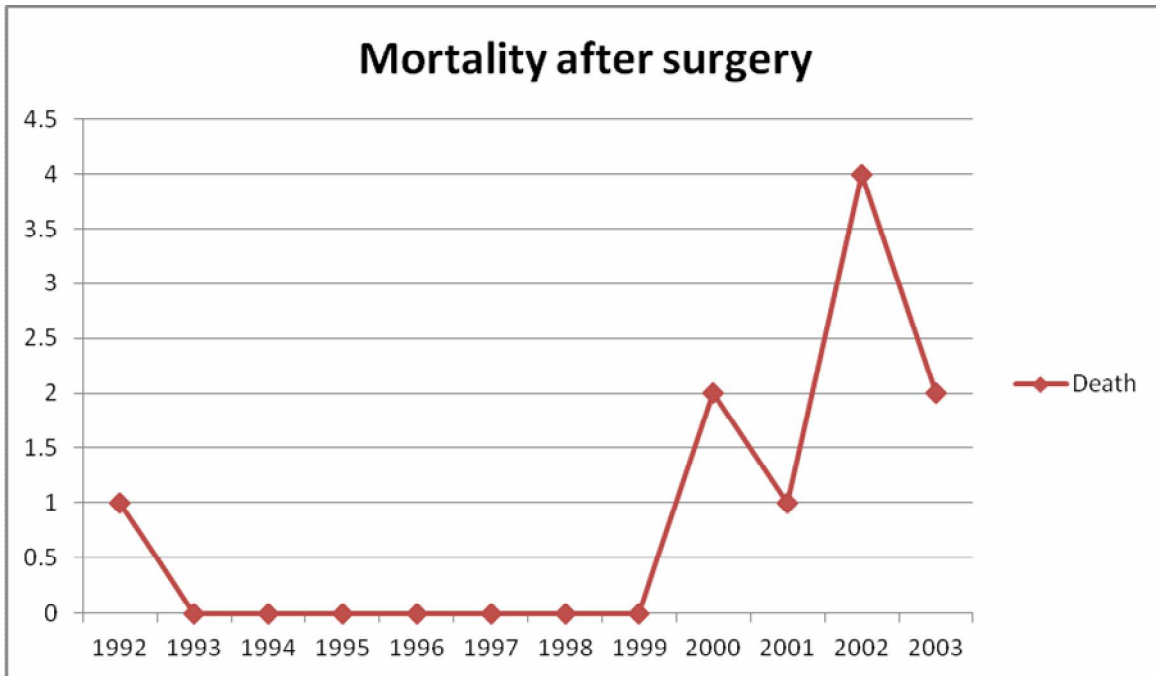


Table 1

	Mean
Age	41.1 years
Onset	11.4 hours
Pulse	95.5 bpm
Systolic BP	111.65 mm of Hg
Total Leucocyte count	8271.3/ml
Peritoneal Contamination	718.27 ml
Size of perforation	7.08mm

Discussion:

**Discussion:**

Perforation constitutes one of the major complications of duodenal ulcers. It is estimated that 0.3% of patients with duodenal ulcers perforate annually [3]. There have been a few Indian studies which estimate the rate of perforation from 4-25% of peptic ulcers [6,7,8].

The earliest account of operative treatment for a perforated peptic ulcer was by Miculicz in 1887 and the first report in the English language of a successful operation for a perforated duodenal ulcer was by Dean in 1894. He had sutured the edges together, washed the abdominal cavity and closed without drains. Two years later Bennett suggested the use of omentum to plug the defect in cases with large perforations [9]. Celian-Jones (1929) and Graham (1937) later showed the simplicity and effectiveness of the procedure [10]. Later in the 90s with the advent of laparoscopic era, even DUP began to be repaired by laparoscopy with good results [11,12]. There have been studies and case reports proving the efficacy of laparoscopic repair in our Indian scenario as well [13,14]. In our study none of the patients have undergone laparoscopy as the instruments were not available for emergency surgery during the study period.

With the advances in the medical therapy the incidence of elective surgery for peptic ulcer disease has decreased, but the incidence of emergency surgery has remained constant or has increased over the last decade [4,5]. In our study it was noted that between the late 90s and early 2000 the number of patients undergoing emergency surgery for DUP has increased.

A couple of decades back it was advisable to add a definitive acid reduction procedure to primary closure of perforation [3]. Presently, primary closure with an omental patch or with a Grahams patch is the recommended procedure as ulcer recurrence can be prevented in most patients by medical regimen designed to eradicate *Helicobacter pylori* [2,5,15,16,].In the initial years of our study period, 5(1.66%) patients with chronic duodenal ulcer underwent a definitive procedure.

In ideal circumstances a perforated duodenal ulcer should be operated at the earliest after preoperative resuscitation [3,9,5]. Late presentation and delayed surgery has been associated with increased morbidity and mortality. In our study the mean delay in presentation has been 11 hours, this has been attributed to multiple factors like non-availability of transportation and long travel distances, sometimes up to 100 kilometres. There is an association of NSAID with peptic ulcer disease [1,4], in our study 16 (5.3%) of patients had a history of NSAID consumption.

The incidence of a complication and mortality following emergency surgery for DUP observed in our study is in concordance with other international studies [17,18]. In our study, 18 (5.96%) patients developed a bile leak following the surgery which is comparable to other studies which have mentioned the leak rate ranging from 0.5- 9% [17,19,20,21,22,23].

### **Conclusion:**

The presentation of patients, trend of surgical procedure and the associated morbidity and mortality is similar to other studies. In our study, incidence of emergency surgery and

consequently leak rate and mortality has increased in early 2000s this could be attributed to changing patient demographics and needs to be studied further.

References:

**References:**

- I. Johnston D, Martin I. Duodenal ulcer and peptic ulceration. In: Zinner MJ, Schwartz SI, Ellis H, Eds. Maingots abdominal operations, Vol 1, 10<sup>th</sup> ed. Boston McGraw Hill International. 2001: p 941-969.
- II. S Paterson-Brown. Stomach and duodenum: In. Ellis BW, S Paterson Brown, Eds. Hamilton Baileys Emergency Surgery, 13<sup>th</sup> ed. London. 2000: p 343-356.
- III. Debas HT, Mulvihill SJ. Complications of peptic ulcer. In: Zinner MJ, Schwartz SI, Ellis H, Eds. Maingot's Abdominal Operations, Vol 1, 10<sup>th</sup> ed. Boston McGraw Hill International. 2001: p 981-997.
- IV. Kitagawa Y, Dempsey DT. Stomach. In: Brunicaardi FC, Andersen DK, Billiar TR, Dunn DL, Hunter JG, Matthews JB, Pollock RE, Eds. Schwartz,s Priciples of Surgery, 10<sup>th</sup> ed. McGraw-Hill Education. 2015: 1035-1098.
- V. Broderick TJ, Matthews JB. Ulcer complications. In: Zinner MJ, Ashley SW, Eds. Maingots abdominal operations, 11<sup>th</sup> ed. McGraw Hill International. 2007: p 353-375.
- VI. Khuroo MS, Mahajan R, Zargar SA, Javid G, Munshi S. Prevalence of peptic ulcer in India: an endoscopic and epidemiological study in urban Kashmir. Gut: 1989; 30: 930-934.

- VII. Malhotra SL. Epidemiological study of peptic ulcer in the South India. *Gut*: 1967; 8: 180-8.
- VIII. Raghvan P. Epidemiology of peptic ulcer in an urban community in Chandigarh, Bombay, India. *Gastroenterology*: 1962; 42: 130-43.
- IX. Chalstrey LJ. Perforated peptic ulcers. In: Schwartz SI, Ellis H, and Husser WC, Eds. *Maingot's Abdominal Operations, Vol 1, 8<sup>th</sup> ed*; Connecticut Apleton-Century-Crofts. 1985: p 775-798.
- X. Graham RR. The Treatment of perforated duodenal ulcer. *Surg Gyn & Obs*: 1937; 235-238.
- XI. Nathanson LK, Easter DW, Cuschieri A. Laparoscopic repair/ peritoneal toilet of perforated duodenal ulcer. *Surg Endosc*. 1990;4(4):232-3.
- XII. Lau WY, Leung KL, Kwong KH, Davey IC, Robertson C, Dawson JJ, et al. A randomized study comparing laparoscopic versus open repair of perforated peptic ulcer using suture or sutureless technique. *Ann Surg*. 1996;224(2):131-8.
- XIII. Mehendale VG, Shenoy SN, Joshi AM, Chaudhari NC. Laparoscopic versus open surgical closure of perforated duodenal ulcers: a comparative study. *Indian J Gastroenterol* 2002; 21:222-4
- XIV. Momin ER, Kamat MM, Upadhye A, Kumar S. Laparoscopic management of a perforated duodenal ulcer, case report from a municipal hospital. *IJABMS*.2014;16b(23):68-74.
- XV. Stabile BE. Role of surgery for perforated duodenal ulcer in helicobacter pylori era. *Ann Surg*: 2000; 231(2): 159-160.

- XVI. Gilliam AD, Speake WJ, Lobo DN, Beckingham IJ. Current practice of emergency vagotomy and *Helicobacter pylori* eradication for complicated peptic ulcer in the United Kingdom. *Br J Surg*: 2003; 90: 88-90.
- XVII. Wilhelmsen M, Moller MH, Rosenstock S. Surgical complications after open and laparoscopic surgery for perforated peptic ulcer in a nationwide cohort. *Br J Surg*: 2015; 102(4): 382-7.
- XVIII. Søreide K, Thorsen K, Harrison EM, Bingener J, Møller MH, Ohene-Yeboah M, Søreide JA. Perforated peptic ulcer. *Lancet*: 2015; 386 (10000): 1288-98.
- XIX. F. Vărcuæ, F. Lazăr, M. Beuran, I. Lica, C. Turculeă, E.A. Nicolau. Laparoscopic Treatment of Perforated Duodenal Ulcer – A Multicentric Study. *Chirurgia*: 2013; 108 (2): 172-176.
- XX. Aljohary H, Althani H, Elmabrok G, Hajaji K, Taha I. Outcome of laparoscopic repair of perforated duodenal ulcers. *Singapor Med J*: 2013; 54(4): 216-219.
- XXI. Thorsen K, Glomsaker TB, Von Meer A, Søreide K, Søreide JA. Trends in Diagnosis and Surgical Management of Patients with Perforated Peptic Ulcer. *J Gastrointest Surg*: 2011; 15:1329–1335.
- XXII. Budzyński P, Pędziwiatr M, Grzesiak-Kuik A, Natkaniec M, et al. Changing patterns in the surgical treatment of perforated duodenal ulcer – single centre experience. *Videosurgery Miniinv*: 2015; 10 (3): 430–436.
- XXIII. Hemmat M, Ghaffari A. Generalized Peritonitis Requiring Re-operation After Leakage of Omental Patch Repair of Perforated Peptic Ulcer. *Saudi J Gastroenterol*: 2011; 17(2): 124–128.