

15

DOI:

## **SCLERAL LENSES – A BETTER OPTION FOR KERATOGLOBUS**

Optom. Naeem Meman<sup>1</sup>, Dr. Usman Memon<sup>2</sup>

<sup>1</sup>B. Optom, Pursuing M. Optometry, Nagar School of Optometry, Ahmedabad, <sup>2</sup>PhD, M. Optom, FIACLE (Aus.), Director, Vision Venture Eye Care Hospital, Ahmedabad

### **ABSTRACT**

**PURPOSE:** To understand effect of Scleral lens on Keratoglobus cornea.

**CASE STUDY:** Prospective Case Study

**METHOD:** A 19-year old male diagnosed with RE Keratoglobus and LE Keratoconus was given a trial of Scleral contact lenses (Comfort- 15), to understand vision development and rehabilitation when no other corrective option was giving fruitful results for vision rehabilitation.

Upon trial final lens was chosen with respect to comfort, vision improvement for distance and near and visual rehabilitation, and was dispensed lens with follow-up of 1-week, 1-month, 3-month & 6-months.

**RESULT:** With final lens patient was comfortable with wearing hours of 10-12 hours comfortably with vision restoration to both eyes 6/6; N6 from RE 6/60 and LE 6/24; N10 both eyes.

**CONCLUSION:** Scleral lenses have been proven to be better corrective option for keratoglobus and keratoconus.

**KEY WORDS:** Sclera, Lenses, Keratoglobus

### **INTRODUCTION:**

Keratoglobus is a bilateral ectatic disorder that is usually non progressive or minimally progressive. The typical globular protrusion of the cornea results from generalized thinning, most marked in the periphery, associated scleral thinning has also been described. <sup>[1]</sup>

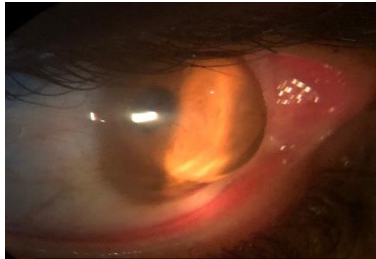
Keratoglobus can occur in the fellow eye of a patient with PMD, Pouliquen et al. have also described unilateral keratoglobus occurring in a patient with pre-existing keratoconus. <sup>[1]</sup>

Keratoconus is a clinical term used to describe a condition in which the cornea assumes a conical shape because of thinning and protrusion. The process is conventionally thought to be non-inflammatory. Cellular infiltration and vascularization do not occur. It is usually bilateral, although it may present with marked asymmetry. Disease typically involves the central two thirds of the cornea with the apex of the cone usually centred just below the visual axis. This disease process results in mild to marked impairment of visual function. <sup>[1]</sup>

Patients diagnosed with corneal ectasia and irregular astigmatism can be a challenge to fit with contact lenses such as soft, conventional corneal gas permeable (GP), hybrid and piggyback contact lenses all come with limitations that stymie success. For example, soft contact lenses may not provide adequate visual acuity, standard GP lenses can decenter or dislodge and the intricacies of piggyback lens systems can be difficult for some patients. In addition, the location or amount of corneal irregularity often makes it impossible to achieve an adequate fit with these contact lenses. <sup>[2]</sup>

Fortunately, scleral lenses can solve many of these problems. Scleral lenses are large-diameter GP lenses with high DK that vault over the cornea and rest on the conjunctiva and sclera, masking corneal irregularity. [2]

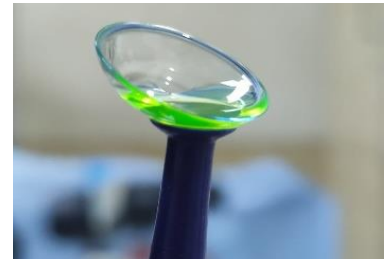There are many indications for scleral lenses for irregular corneas with ectasia, including for keratoconus, keratoglobus and pellucid marginal degeneration. [2]



[ ]



[ ]



[ ]

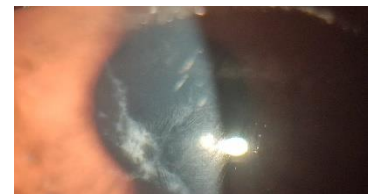**KEY WORDS:** Keratoglobus | Keratoconus | Scleral Lens | Scleral vault | Dk

**CASE DISCUSSION:**

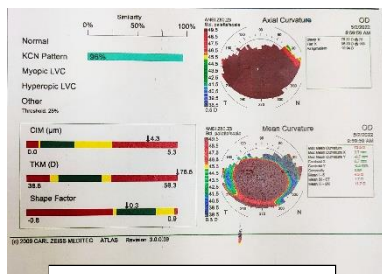
A 19 year old male patient diagnosed with Right Eye Keratoglobus (Grade 4) and Left Eye Keratoconus (Grade 2), for Left Eye CXL surgery was done on 20/12/21, but for Right Eye the corneal pachymetry was too thin (300 microns) to consider for CXL. This was challenge to cadre for rehabilitation of vision as teenage patient. Upon discussion with patient and guardian as well considering his active student life style, scleral lens was chosen for the trial.

**Subjective and Objective findings**

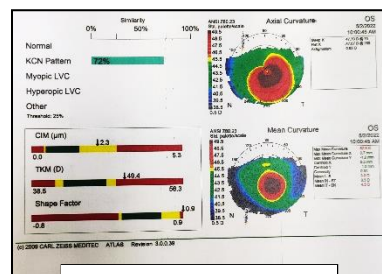
- **Refraction**  
 Vision: OD – 6/60                    - No Improvement  
                   OS – 6/24                    - No Improvement
- **Corneal Topography:** see topography images OD and OS.



OD: Corneal Ectasia with Apical Scarring (Actual image)



Topography Image: OD



Topography Image: OS


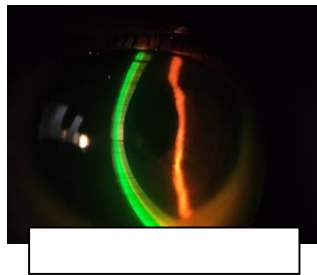
- **Slit Lamp Examination:**

OD	OS
Extreme Corneal Ectasia (Keratoglobus)	Corneal Ectasia
Cornea : Extreme Shape & Thinning	Corneal Thinning
Corneal Scarring : Central to Para Central	Fleischer's ring

- **Pachymetry :** OD – 300 Microns  
OS – 390 Microns

**FIRST LENS FOR TRIAL:** (selected based upon manufacturer's guideline)

OD	Trial lens details	OS
7.30	B.C.	7.70
<b>4630 μ</b>	Sag	4140 μ
-2.50 Dsph	Base Power	-0.50 Dsph
15 mm	Diameter	15 mm
Standard	Edge Profile	Standard



OD	Post Fit Evaluation (with trial lens)*	OS
<b>250 μ</b>	<b>Fluid Reservoir (Central Fit)</b>	210 μ
<b>100 μ</b>	<b>Fluid Reservoir (Limbal Fit)</b>	90 μ
Mild Blanching	<b>Landing zone</b>	Mild Blanching
Stable	<b>Lens Orientation</b>	Stable
+0.00/-1.50*170	<b>Over – Refraction</b>	+0.50/-0.50*20
6/6p ; N8	<b>Vision</b>	6/6 ; N6

\* Post- fit Evaluation was carried out after settling time of 45 minutes of Trial Lens insertion

OD	Final Ordered lens details <sup>#</sup>	OS
7.30	B.C.	7.70
<b>4630 μ</b>	Sag	4140 μ
-2.50/-1.50*170	Power	0.00/-0.50*20
15 mm	Diameter	15 mm
+1.50	Edge Profile	+1.00

OD	Post Fit Evaluation (with final lens)*	OS
6/6p ; N8	<b>Vision</b>	6/6 ; N6
<b>250 μ</b>	<b>Fluid Reservoir (Central Fit)</b>	210 μ
<b>100 μ</b>	<b>Fluid Reservoir (Limbal Fit)</b>	90 μ
Aligned	<b>Landing zone</b>	Aligned
Stable	<b>Lens Orientation</b>	Stable

# Final

Ordered lens was Comfort 15 standard lens with toric prescription and non-toric periphery

#### Tips & Methods for insertion & removal

- Plungers used for insertion is non-suction based big plunger while for removal of lens is suction based small plunger.
- For cleaning & storage of lens Alcon Pure moist (MPS) is advised as well for enhanced cleaning Boston Simplus is advised at alternate nights.
- Silver Line Pro Saline Max is advised to fill inside scleral lens to vault over cornea.
- Adequate training was provided in OPD for insertion and removal of scleral contact lenses.

#### 1 week Follow-up visit

On 1<sup>st</sup> week of follow-up very faint impingement ring was observed on removal of lens, which in fact was reduced from day 1 after removal of lens. Slight discomfort was felt in right eye, which is expected to get adapted, will wait and watch until next follow-up.

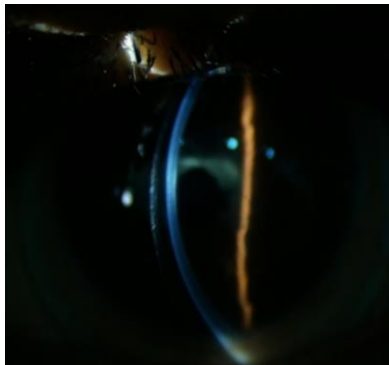
Few teething issue while insertion of lens in right eye was present which was resolved upon re-explanation and training

#### 1<sup>st</sup> & 3<sup>rd</sup> month Follow-up visit

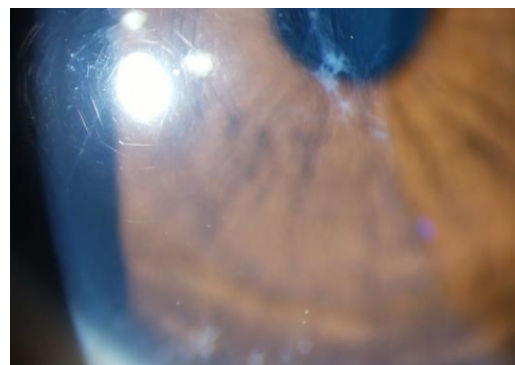
At the time of 1<sup>st</sup> & 3<sup>rd</sup> month follow-up, He was happily wearing the lenses, the wearing time was acceptable though, with 10 to 12 hours for the both eyes. We will keep monitoring him to see how he is doing on follow-ups.

### 6 month Follow-up visit

The patient has been seen regularly over 6 months, which was necessity in the given circumstances and corneal condition. There was complaint of blurry vision many times in both eye, upon slit lamp examination it was observed few scratches & deposits on lens surface which may be the cause of blurry vision. For removal of deposits Boston simplus was advised for everyday cleaning at night time which earlier was advised for alternate nights.



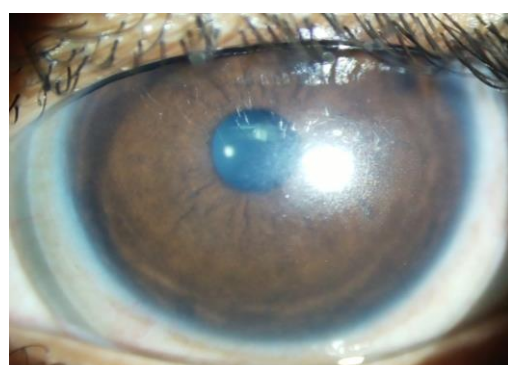OD Vault after 6 months



OD: Minor scratches on lens surface



OS Vault after 6 months



OS: Deposits on lens surface

### DISCUSSION & SUMMARY:

Keratoglobus is one of the three type of primary ectasia that also includes keratoconus and pellucid marginal degeneration. Keratoglobus is a rare condition, in which basically entire cornea from limbus to limbus bulges out. [3]

These are extreme difficult cases to fit with corneal lenses, and scleral lenses are almost by default the preferred option because they bridge over entire cornea. However, as this case indicates, extremely high levels of vault may be necessary to achieve this in some patients. [3]

OD		OS
Grade 4 Keratoglobus	Grade	Grade 2 Keratoconus
6/60	Vision (Unaided)	6/24
Corneal severe ectasia with apical scarring	SLE	Cornea Clear with fleischer's Ring
<b>300 μ</b>	Pachymetry	390 μ
K1 76.33 D @ 70, K2 65.39 D @ 160	Topography	K1 47.70 D @ 75, K2 47.07 D @ 165
Not advisable	CXL Surgery	Done on 20/12/21
	<b>Trial Lens Details</b>	
<b>4630 μ</b>	Sag	4140 μ
7.30 mm	B.C.	7.70 mm
-2.50 Dsph	Base Power	-0.50 Dsph
<b>250 μ</b>	Vault	210 μ
Plano/-1.50*170	Over-refraction	+0.50/-0.50*20
6/6p	Vision (with scleral lens )	6/6

**ACKNOWLEDGEMENT:** NIL

**FUNDING:** - NIL

**CONFLICT OF INTEREST:** NIL

**REFERENCES:**

1. Cornea : fundamentals, Diagnosis & Management By *Mark J. Mannis & Edward J. Holland*
2. The Right Fit for the Irregular Cornea: Smooth Things Over with Scleral Lenses By *Melissa Barnett, O.D.*
3. Scleral Lens Case Report Series : Beyond the Corneal Borders : Keratoglobus By *Jan Pauwels, Carina Koppen and Inge Leysen*