

A RARE CASE OF TEMPOROPARIETAL ANEURYSMAL BONE CYST

Dr Yajurvendra Gohil, Dr Uday Pratap, Dr Mukesh P Patel

Department of Neurosurgery SVP Hospital and NHL medical college Ahmedabad Pin 380008, pratapuday14740@gmail.com

ABSTRACT

Introduction: Aneurysmal bone cyst is a benign non-neoplastic expansile osteolytic lesion with a thin wall, containing blood-filled cystic cavities. It usually occurs in long bones. Aneurysmal bone cyst in skull is very rare accounting for only 3-6% of total case of aneurysmal bone cyst. Treatment of choice is total surgical excision of the aneurysmal bone cyst. Here is a case of a 10-year-old girl who presented with a tumour over right temporoparietal region of skull. Radiological investigations showed the tumour to be aneurysmal bone cyst. The girl was operated upon for excision of right temporoparietal space occupying lesion.

Observation: A 10 years old girl presented with gradually increasing mildly tender swelling in the right temporo-parietal region for the last 8 months. Patient had complaint of occasional headache. There was no history of trauma. On physical examination, it was a tender, approximately 8 x 8 x 4 cm mass in the right temporo-parietal region, which was firm and fixed to the bone having a smooth surface. Skin over the swelling was normal. There was no neurological deficit. **CONCLUSION:** An aneurysmal bone cyst in skull is very rare and particularly rarer in temporo-parietal region. Thus, ours is a very rare case. As part of the treatment, we performed complete surgical excision of the tumour which is considered an ideal treatment of the aneurysmal bone cyst. Histopathological examination of the specimen confirmed the lesion to be the aneurysmal bone cyst.

Keywords: TEMPOROPARIETAL, ANEURYSMAL, ANEURYSMAL BONE CYST

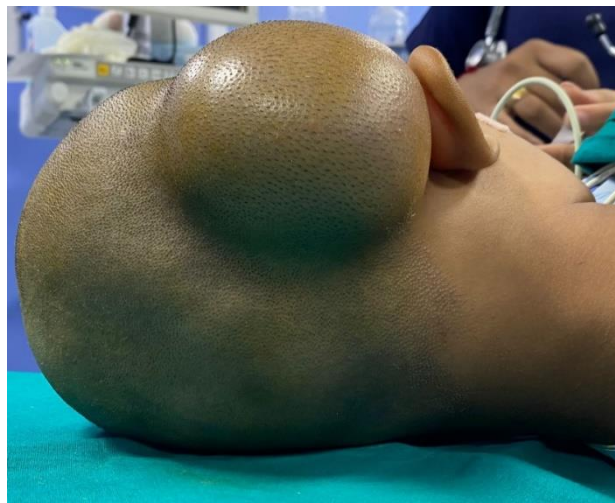INTRODUCTION

Aneurysmal bone cyst is a benign pathological lesion composed of large vascular spaces separated by trabeculae of connective tissue and bone. Exact pathogenesis is not yet known. Aneurysmal bone cyst most commonly occurs in long bones and vertebrae and only rarely (3-6%) are found in skull. In skull most commonly involved parts are frontal, occipital and temporal bone^[1]. Almost 80% of the patients are under age of 20 years with slight female preponderance. Ideal treatment of these tumours is total surgical excision. There are 40-50% chances of recurrence after subtotal resection of aneurysmal bone cyst.

CASE REPORT

A 10 years old girl presented with gradually increasing mildly tender swelling in the right temporo-parietal region for the last 8 months. Patient had complaint of occasional headache. There was no history of trauma. On physical examination, it was a tender, approximately 8 x 8 x 4 cm mass in the right temporo-parietal region, which was firm and fixed to the bone having a smooth surface. Skin over the swelling was normal. There was no neurological deficit.

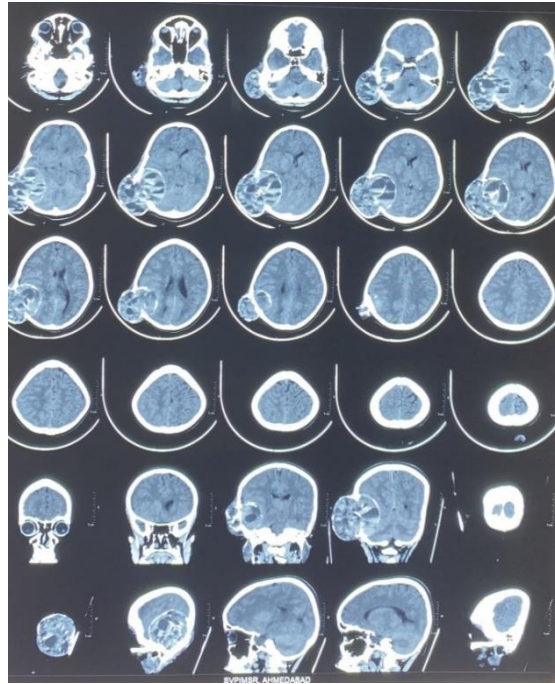
All routine investigations were within normal limits. X-ray skull revealed a round well



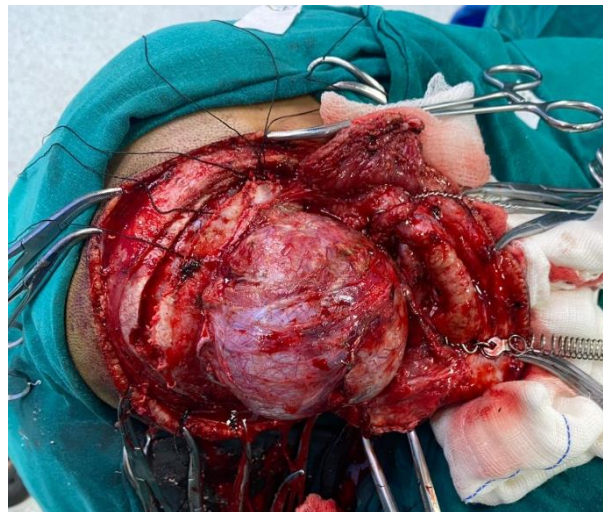
defined radioluscent area in the right temporo-parietal region with distension of periosteum outlined by a very thin subperiosteal bone.

MRI Brain (plain and contrast) was suggestive of well circumscribed solid cystic altered signal intensity calvarial lesion in right temporo-parietal region with bony defect. The lesion showed multiple internal fluid-fluid levels, heterogeneous solid component with haemorrhagic component within the lesion. On post contrast study, there was evidence of peripheral intense enhancement and multiple thick enhancing septations within the cystic component.

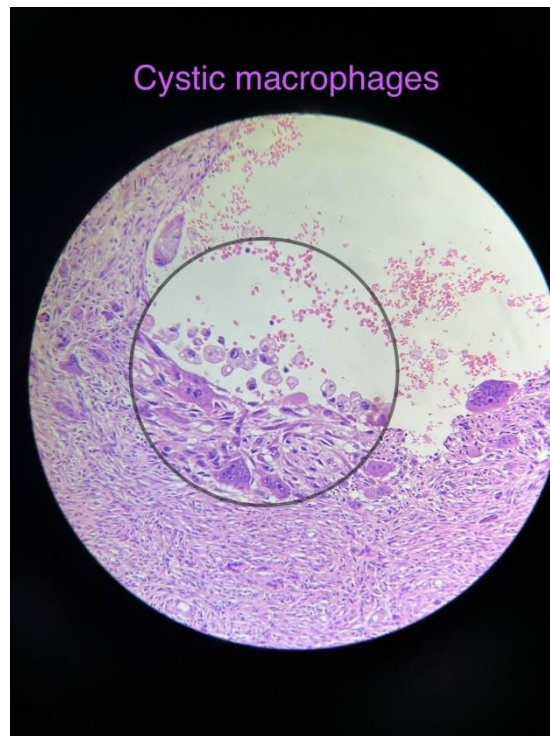
CT Brain (plain) was suggestive of well circumscribed solid cyst mixed density calvarial lesion with thick septations seen in the right temporo parietal region with large bony defect. Few of the septations showed specks of calcification. The lesion showed multiple internal hyperdense blood-fluid levels, suggestive of hemorrhagic component within the lesion.



Patient was operated for right temporo-parietal craniectomy and total excision of the tumour. Tumour was seen compressing the dura but not invading it. Tumour was dissected carefully and was separated from the dura. Total excision of the tumour was done. Dura was intact following tumour excision. Vascular channels were coagulated. Patient was relieved off her symptoms after the treatment.



Histopathological examination of the tumour specimen showed solid fibroblastic stroma and cystic spaces filled with blood. Multiloculated cysts separated by cellular septa containing fibroblasts, giant cells and woven bone. Fibroblastic stroma also contained bulging blood vessels, histiocytes, foamy macrophages and osteoclast like giant cells. Reactive bone formation and focally calcified matrix was present. Few mitoses were present but no cytological atypia was seen. All these histopathological findings were suggestive of aneurysmal bone cyst.



DISCUSSION:

Aneurysmal bone cyst is a benign bone lesion usually occurring in long bones and vertebrae. It rarely occurs in skull. Jaffe and Lichtenstein in 1942 first described aneurysmal bone cyst as a fluid filled unicameral cavity located in the interior of a bone and delimited by a more or less thinned and expanded shaft cortex. [2] It usually occurs in 2nd decade of life with slight female preponderance. In the skull aneurysmal bone cyst mostly occurs as a swelling or the mass over the scalp. Trauma is usually implicated as etiological factor but exact etiology is yet unknown. Aneurysmal bone cyst may coexist with other lesions of bone such as fibrous dysplasia, unicameral bone cyst, giant cell tumour, chondroblastoma [3], [4].

CT scan and MRI are radiological investigations which are useful in suggesting diagnosis of aneurysmal bone cyst. CT scan usually shows an expansile lytic lesion with widening of diploic spaces, septations and a well-defined thin margin. MRI shows usually a well-defined expansile mass with internal septations that divides into small cavities. The internal cysts present low-to-medium signal intensity on T1-weighted images and high intensity on T2-weighted images. After gadolinium injection, the peripheral capsule and internal septations enhance strongly. The hallmark of aneurysmal bone cyst is fluid-fluid level that represent the sedimentation of red blood cells in haemorrhagic cavities [5]. All of the above radiological findings were present in our case including characteristic fluid-fluid levels. To rule out similar lesions elsewhere in the body most commonly seen in vertebra and chest, we performed x-ray of the whole spine and chest x-ray which showed no similar bone lesions. Pathologically, on gross examination, aneurysmal bone cyst consists of fluid-filled cavities with septations. On microscopic examination, aneurysmal bone cyst consists of fibroblasts,

myofibroblast and histiocytes with fluid filled cavities separated by septations containing fibroblasts and woven bone. In our case, same histopathologic findings were seen with solid fibroblastic stroma and cystic spaces filled by blood. Multiloculated cysts separated by cellular septa containing fibroblasts, giant cells and woven bone. Few mitoses were seen but no cytological atypia was seen.

Treatment is complete surgical excision of the aneurysmal bone cyst. If complete surgical excision is not possible, partial removal is done but recurrence rate is high in partial removal. Radiotherapy may be considered in incomplete removal or where tumour cannot be excised because of its location but its effectiveness is not clearly proven. Endovascular embolization is considered in some cases to devascularise the lesion to reduce intraoperative bleeding. In our case we did complete surgical excision of the aneurysmal bone cyst. Radiotherapy was not advised to our patient.

CONCLUSION:

An aneurysmal bone cyst in skull is very rare and particularly rarer in temporo-parietal region. Thus, ours is a very rare case. As part of the treatment, we performed complete surgical excision of the tumour which is considered an ideal treatment of the aneurysmal bone cyst. Histopathological examination of the specimen confirmed the lesion to be the aneurysmal bone cyst.

REFERENCES:

1. Robert H. Wilkins, Setti S. Rengachary; Neurosurgery; 2nd edition; McGraw-Hill
2. Jaffe HL, Lichtenstein L. Solitary unicameral bone cyst with emphasis on the roentgen picture, the pathologic appearance and the pathogenesis. *Arch Surg.* 1942; 44:1004–1025. doi: 10.1001/archsurg.1942.01210240043003.
3. Tillman BP, Dahlin DC, Lipscomb PR et al : Aneurysmal bone cyst. An analysis of ninety-five cases. *Mayo Clin Proc* 1968; 43: 478-495.
4. Biesecker JL, Marcove RC, Huvos AC et al : Aneurysmal bone cysts. A clinicopathologic study of 66 cases. *Cancer* 1970; 26: 615-625.
5. Harmann A., Polivca M., Loit M., Guichard J., Bousson V. Aneurysmal bone cyst of the frontal bone-a radiologic-pathologic correlation. *Journal of Radiology case reports*; 2018 July; 12(7):16-24

Acknowledgements: none

Conflicts of interest: none

Funding: Nil